



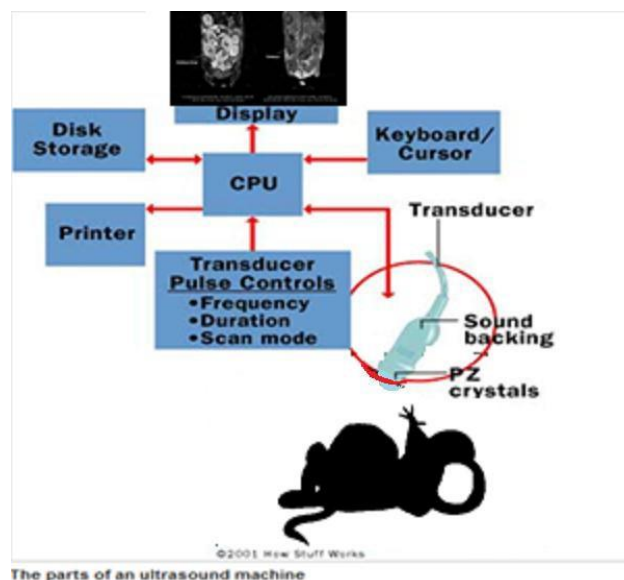
<b>University Animal Care Committee Standard Operating Procedure</b>		
<b>Document No:</b> 7.23	<b>Subject:</b> Rodent Ultrasound (Mice)	
<b>Date Issued:</b> June 25, 2015	<b>Revision:</b> 3	<b>Page No:</b> 1

**Location:** Queen's University

**Responsibility:** Principal Investigators (PI), Research Staff, Veterinary Staff

**Purpose:** The purpose of this Standard Operating Procedure (SOP) is to describe basic cardiac and reproductive ultrasound processes for rodents.

1. **Introduction and Definitions:** 'Ultrasound' refers to sound waves with a frequency too high for humans to hear. In general, ultrasound used clinically is in the range 1-18 MHz; however, rodent machines operate at a much higher frequency to get far better resolution (typically 40-70MHz). Ultrasound images (sonograms) are made by sending a pulse of ultrasound into tissue using an ultrasound transducer. The sound waves hit a boundary between tissues (e.g. between fluid and soft tissue, soft tissue and bone) and are reflected back to the probe and relayed on to the machine, or travel further until they reach another boundary and get reflected. The machine calculates the distance from the probe to the tissue or organ (boundaries) using the speed of sound in tissue (5,005 ft/s or 1,540 m/s) and the time of the each echo's return (usually on the order of millionths of a second). The machine displays the distances and intensities of the echoes on the screen, forming a two dimensional image. Many different types of images can be formed using ultrasound. The most well-known type is a B-mode image, which displays the acoustic impedance of a two-dimensional cross-section of tissue. Other types of images can display blood flow, motion of tissue over time, the location of blood, the presence of specific molecules, the stiffness of tissue, or the anatomy of a three-dimensional region. Compared to other prominent methods of medical imaging, ultrasonography has several advantages that include: 1) the ability to observe structures without the use of radiation; 2) the acquisition of images in real-time (rather than after an acquisition or processing delay); 3) portable imaging instruments; and 4) lower costs versus other common imaging techniques.





University Animal Care Committee Standard Operating Procedure		
<b>Document No:</b> 7.23	<b>Subject:</b> Rodent Ultrasound (Mice)	
<b>Date Issued:</b> June 25, 2015	<b>Revision:</b> 3	<b>Page No:</b> 2

## 2. Materials:

- Various transducer probes - probe that sends and receives the sound waves
- Central processing unit (CPU) - computer that does all of the calculations and contains the electrical power supplies for itself and the transducer probe
- Transducer pulse controls - changes the amplitude, frequency and duration of the pulses emitted from the transducer probe
- Display - displays the image from the ultrasound data processed by the CPU
- Keyboard/cursor - inputs data and takes measurements from the display
- Disk storage device (hard, floppy, CD) - stores the acquired images
- Printer
- Isoflurane and vaporiser
- Heating blanket or discs
- Eye lubricant
- Sterile swabs
- Adhesive tape
- Sterile needles
- Sterile syringes
- Lactated Ringer's solution or sodium chloride
- Depilatory cream (Nair)
- Ultrasound conducting gel (Ecogel)
- Rectal thermometer and lubricant (petroleum jelly)
- Recovery cage

## 3. Procedures:

- Before beginning, turn on the ultrasound system and computer as well as the handling platform (ensure the correct platform is in place, e.g. mouse versus rat). Set-up the study parameters on the computer and ensure your desired transducer is in the active port.
  - Turn on oxygen gas and isoflurane. For induction in an adult mouse or rat use 5% isoflurane in oxygen until the animal has lost its righting reflex, then transfer to the pre-warmed handling platform and the nose-cone. Make sure the flow of inhalational gas has been switched and directed to the platform.
  - Once placed on the handling platform, instill eye lubricant using a sterile swab, and fix limbs to the electrode plates using adhesive tape to enable monitoring of cardiac activity and respiration. For adult animals, maintain anesthetic between 1.5-2% isoflurane in oxygen. Use heart rate as an indicator of depth of anesthesia and ensure the lightest effective anesthetic depth is maintained. Monitor body temperature using the rectal thermometer and ensure body temperature is maintained around 36-37°C.
-



<b>University Animal Care Committee Standard Operating Procedure</b>		
<b>Document No:</b> 7.23	<b>Subject:</b> Rodent Ultrasound (Mice)	
<b>Date Issued:</b> June 25, 2015	<b>Revision:</b> 3	<b>Page No:</b> 3

<b>Mouse heart rate</b>	325-780bpm <b>MEAN=470bpm</b>	<b>CONCERN = +/- 10%</b>
<b>Mouse resting respiratory rate</b>	44-163rr/min <b>MEAN=128rr/min</b>	<b>CONCERN = +/- 10%</b>

- Use depilatory cream (Nair) to remove fur over the desired scanning area. Use lightly dampened gauze to clean the site and ensure all remnants of Nair are removed in order to prevent chemical burns and irritation.
- Place generous amount of warmed, ultrasound-conducting gel (Ecogel) between the area of interest and the ultrasound scanning head.
- Begin scanning using the desired probe. Refer to the manufacturer’s website to identify the most ideal probe for your study. Minimize scanning time/ time under anesthetic as best as possible; under 30 minutes is ideal to prevent a decline in cardiovascular function.

**CARDIAC SCANNING:**

- Many cardiac structural and functional parameters can be calculated based on achieving a B-mode and M-mode image in either parasternal long axis (PLAX) or parasternal short axis (SAX). For PLAX place the transducer horizontally on the thorax and angled parallel to the longest axis of the heart. The left ventricular (LV) apex should be horizontally aligned with the aorta. The M-mode sample volume can then be placed between the anterior epicardium and posterior epicardium. To ensure consistency between scans you can use the presence of papillary muscle in the M-mode cine loop. Papillary muscle should appear as “snow caps” over the posterior endocardium in systole. If strain and strain rate analysis is desired ensure you have one clean B-mode image of the LV where the endo- and epi-cardium is seen clearly around the entire chamber.
- From the B-mode PLAX rotate the probe 90° clockwise to achieve a SAX view. Similar B-Mode and M-mode images and calculations can be taken from this axis.
- Diastolic measurements can be achieved from an apical/ 4-chamber view. This involves lowering the top left corner of the handling platform. The transducer can then be placed nearly horizontal to the platform and at an angle, pressed up onto the animal’s thorax from below. Details on this view (and others) can be found on the manufacturer’s website.
- Upon ultrasound completion, supplement animals with subcutaneous fluids (~1ml of 0.9% NaCl or Lactated Ringer’s solution), place individually in recovery cage, provide heat therapy and monitor until mobile. When fully recovered, animals can be returned to their home cage.
- Close your study on the CPU and save it to an external USB. Toggle off the computer and then turn off the main power switch at the back of the system. Clean up all equipment used. Clean the handling platform with T-spray. GENTLY clean the transducer with water and the dedicated lens-cleaning tissues provided in the imaging suite. Ensure the oxygen and isoflurane have been turned off. Replenish the isoflurane and the ultrasound conducting gel and make note of any supplies that are running low (follow-up with the Imaging Suite manager).



University Animal Care Committee Standard Operating Procedure		
<b>Document No:</b> 7.23	<b>Subject:</b> Rodent Ultrasound (Mice)	
<b>Date Issued:</b> June 25, 2015	<b>Revision:</b> 3	<b>Page No:</b> 4

### REPRODUCTIVE SCANNING:

- Umbilical artery Doppler can be performed on pregnant mice and rats from gestation day 10 onwards. When visualized, the animals abdomen/pelvis the umbilical cord can then be seen connected the crescent-shaped placenta to the fetus. Colour Doppler then can be applied to differentiate between umbilical artery and vein. Ensure the direction of blood flow aligns with the Doppler angle and is at least 60° (the lower the better). Fetal heart rate can then be determined from the umbilical artery PW Doppler cine loop. Spiral arteries and maternal channels are not visible enough in mouse to measure blood flow.
- The uterine artery can be identified in pregnant or non-pregnant females as running anterolaterally, posterior to the bladder. To ensure the correct vessel has been isolated follow it back to its branching points, all the way to the aorta. As another measure to ensure you have the correct vessel, look for the PW signal that is characteristic for the uterine artery (can be found in online publications or on the manufacturers' websites). Colour Doppler can also be used to ensure correct direction of flow. Again, ensure the Doppler angle is set parallel to the direction of blood flow and is under 60°. Beam angle correction can be performed to ameliorate and optimize the Doppler angle. From the PW Doppler cine loop, uterine artery peak flow velocity, mean flow velocity, resistance index and pulsatility index can be calculated post-acquisition.
- Upon ultrasound completion, supplement animals with subcutaneous fluids (~1ml of 0.9% NaCl or Lactated Ringer's solution), place individually in recovery cage, provide heat therapy and monitor until mobile. When fully recovered, animals can be returned to their home cage.
- Close your study on the CPU and save it to an external USB. Toggle off the computer and then turn off the main power switch at the back of the system. Clean up all equipment used. Clean the handling platform with T-spray. GENTLY clean the transducer with water and the dedicated lens-cleaning tissues provided in the imaging suite. Ensure the oxygen and isoflurane have been turned off. Replenish the isoflurane and the ultrasound conducting gel and make note of any supplies that are running low (follow-up with Imaging Suite manager).

### References:

<https://www.aspectimaging.com/>

*Revised: October 15, 2015 / February 28, 2019 / February 28, 2022*

---